

Choroidal Rupture with Development of Choroidal Neovascular Membrane (CNVM)

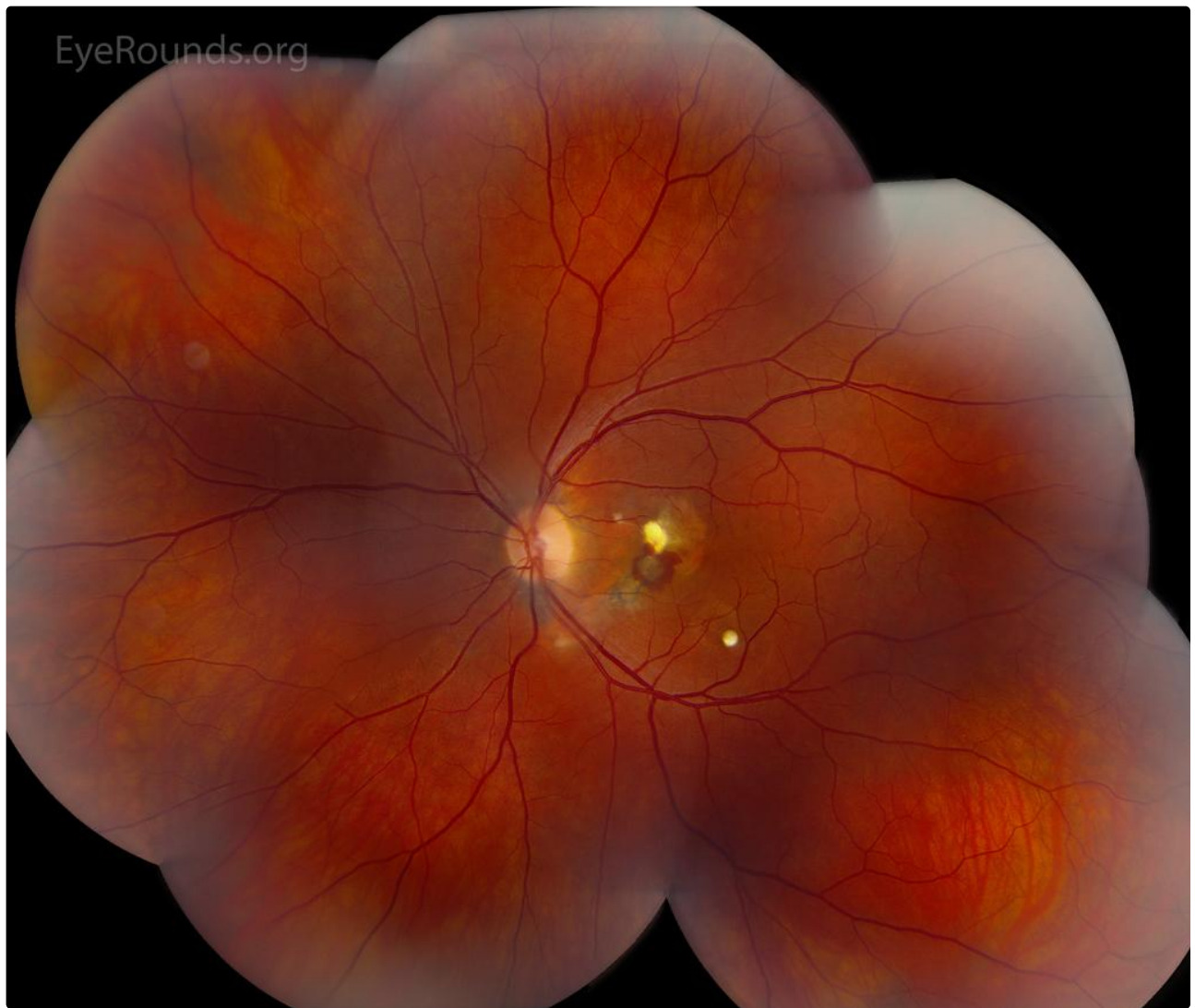
Category(ies): Retina, Vitreous

Contributor: [Johanna Beebe, MD](#)

Photographer: Stefani Karakas, CRA



This is a 40-year-old male who presented with acute onset of metamorphopsia in the left eye (OS). He was a baseball pitcher in college and had a straight line drive injury to the left eye 20 years prior. This same trauma had also occurred in the right eye (OD) the following year. He had no other ocular history including no history of ocular surgery. His visual acuity was 20/20 OD and 20/30 OS, with normal intraocular pressure OU. There was no relative afferent pupillary defect. Anterior segment exam was normal, except for 360 degrees of angle recession OD and 270 degrees of angle recession OS. Dilated fundus exam was normal OD. There was a curved, fibrotic scar concentric to the disc in the left eye with associated hyperpigmentation and overlying intraretinal hemorrhage. There was also atrophy superiorly. In the infratemporal macular there was a round fibrotic scar with signs of previous intraretinal fluid. OCT OS showed a pigment epithelial detachment with associated subretinal and intraretinal fluid. The patient was diagnosed with a choroidal neovascular membrane and treated with intravitreal avastin.



 Enlarge

 Download

Image Permissions:



Ophthalmic Atlas Images by [EyeRounds.org](https://www.eyerounds.org), [The University of Iowa](https://www.theuniversityofiowa.edu) are licensed under a [Creative Commons Attribution-NonCommercial-NoDerivs 3.0 Unported License](https://creativecommons.org/licenses/by-nc-nd/3.0/).

Address

University of Iowa
Roy J. and Lucille A. Carver College
of Medicine
Department of Ophthalmology and
Visual Sciences
200 Hawkins Drive
Iowa City, IA 52242

Legal

Copyright © 2019 The University of
Iowa. All Rights Reserved
Report an issue with this page
Web Privacy Policy |
Nondiscrimination Statement

Related Links

Cataract Surgery for Greenhorns
EyeTransillumination
Gonioscopy.org
Iowa Glaucoma Curriculum
Iowa Wet Lab
Patient Information
Stone Rounds

EyeRounds Social Media

Follow



Receive notification of new cases,
sign up here
Contact Us

